

RianCorp



Case Studies Using LLLT: Lymphoedema

case studies

These case studies have been provided by Australian therapists who use the Riancorp LTU-904 laser therapy unit. Each therapist selects laser treatment areas based on the case, the patient and other constraints. We have provided these to give examples of how Australian therapists are using the LTU-904.

They are provided to offer information only and are not necessarily recommended treatment protocols.

If you have a case study that you would like to add to this booklet, please contact sales@riancorp.com

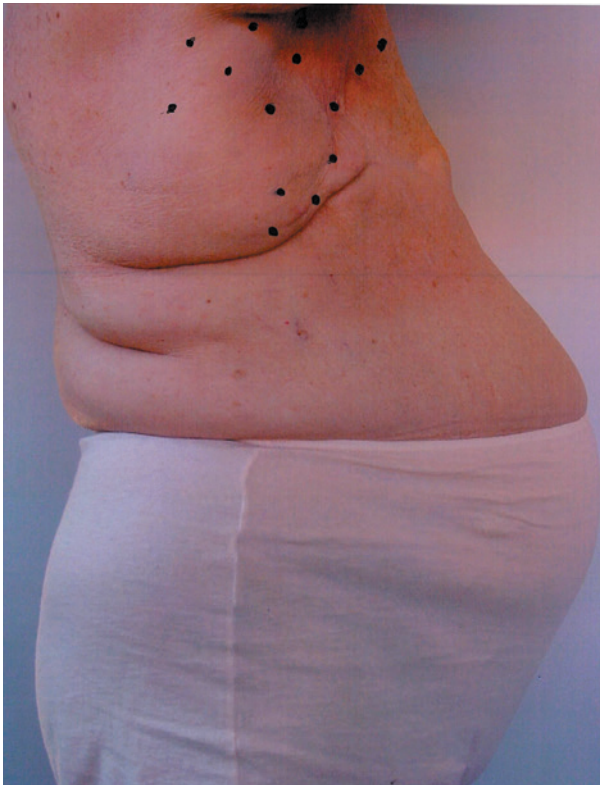case study 1

case history

First Case Bi-lateral Mastectomy – 2001 aged 76 years.

Malignancy both breasts – Axillary clearance Right side 20 nodes Left side 2 nodes. Chemotherapy and radiotherapy to right side only. Postoperative cellulites to right chest wall. Refused to wear arm sleeve.

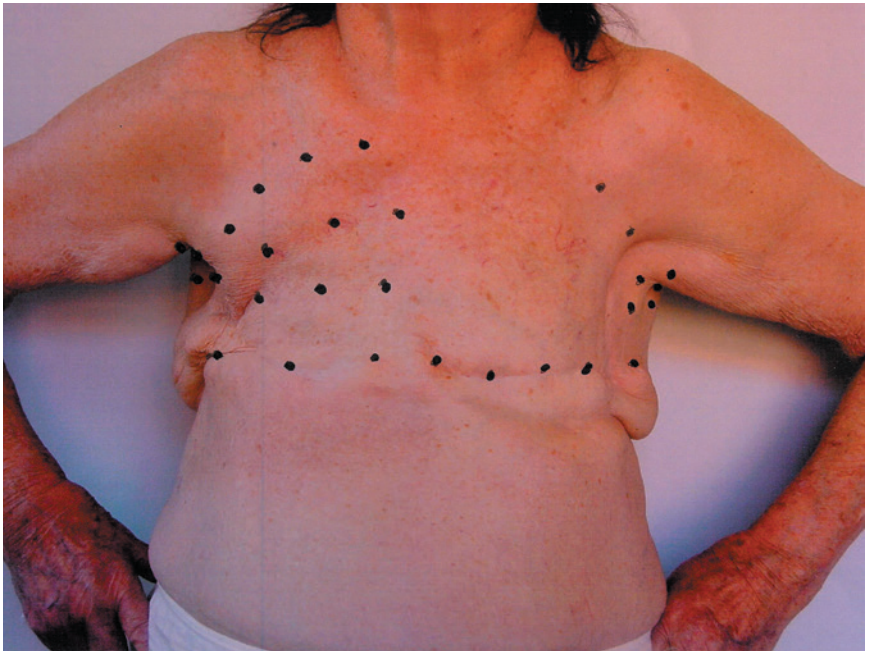
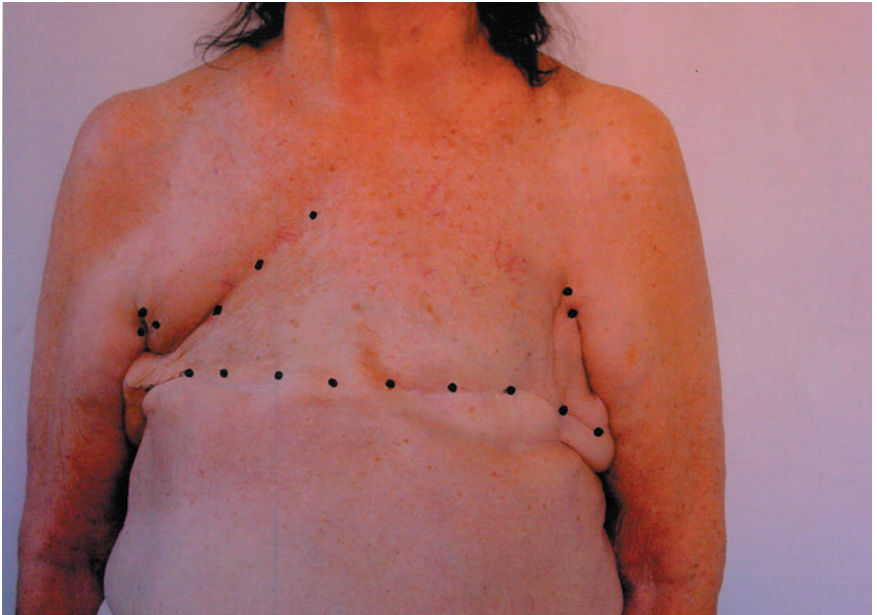
Presented with very mild oedema both arms and red raised scarring to both sides and very large pockets under each arm and enlarged abdomen.



Laser treatment to scar tissue and both axillas (4- 6 places 1 minute each place) and treatment (1 minute per place) to any other tight area.

The above laser treatment was followed by MLD for lymphoedema.

Laser treatment to all areas of fibrosis, the right axilla and the area of irradiation followed by MLD for lymphoedema.



case study 2

case history

Second Case – 58 years

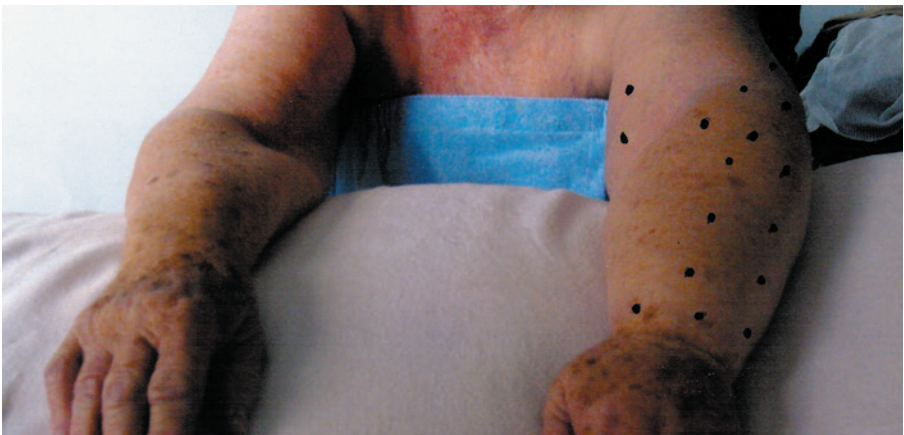1988 – (58 years) Lumpectomy to right breast with complete axillary clearance and radiotherapy to right side. No swelling in right arm.

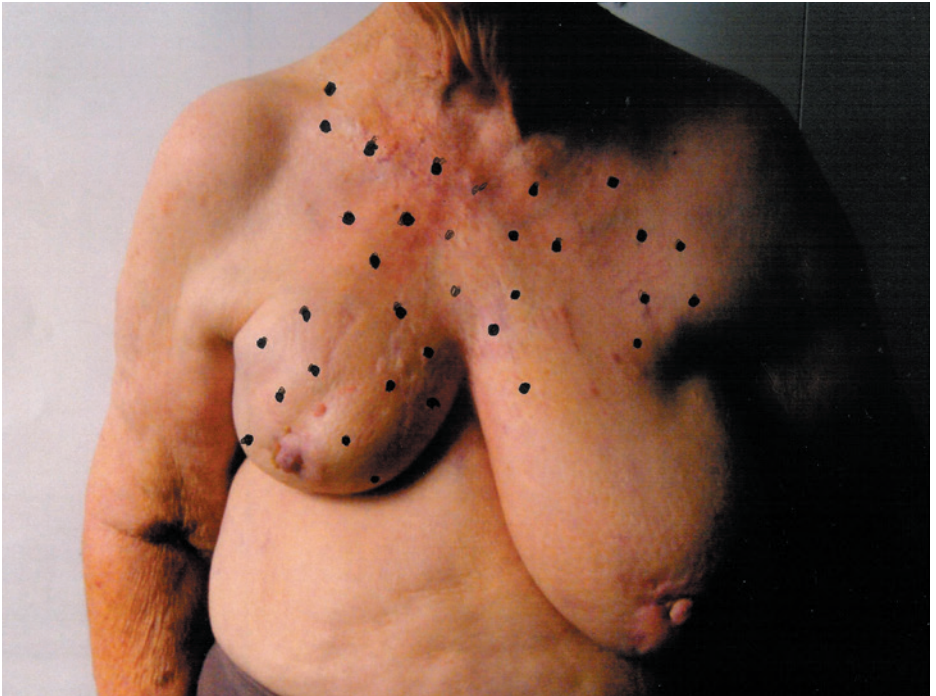
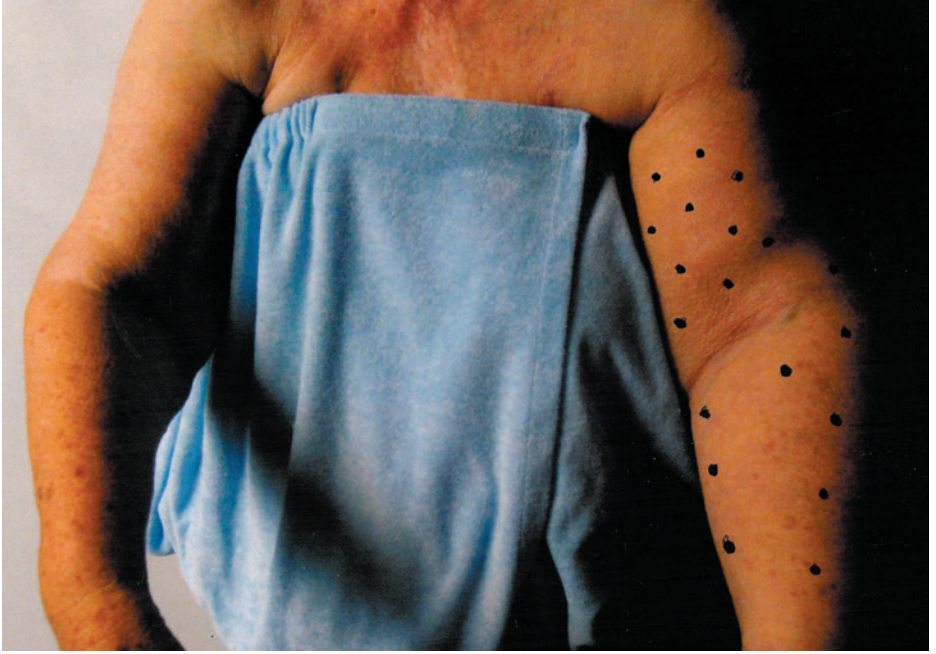2000 – Radiotherapy only to sternum and left side of chest due to malignant lesions in this area. No surgery has been performed on the right side.

2005 – Had a fall which led to oedema in left breast, left arm and abdomen.

No prior treatment has ever been recommended for any of her presenting symptoms.

2008 – (78 years) Commenced treatment. The client presented with lymphoedema in left breast, abdomen and left arm with fibrosis in both medial and lateral aspect of upper arm, elbow area and posterior and anterior aspects of lower arm especially at wrist and along radial catchment. There is also fibrosis on the medial and inferior aspects of the left breast. The fibrosis in the right breast is extremely hard and no movement in the breast tissue.





case study 3

case history 3

Female - 48 years

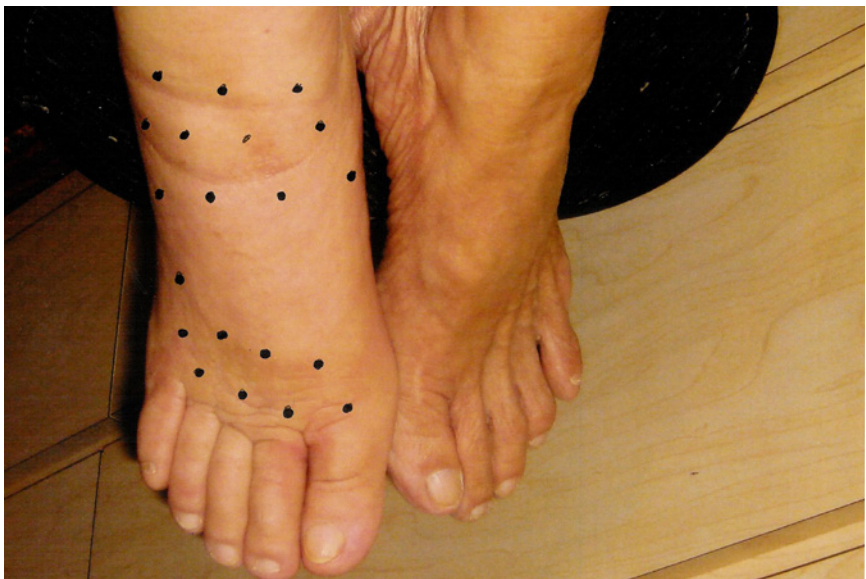Female with secondary lymphoedema following liver transplant.

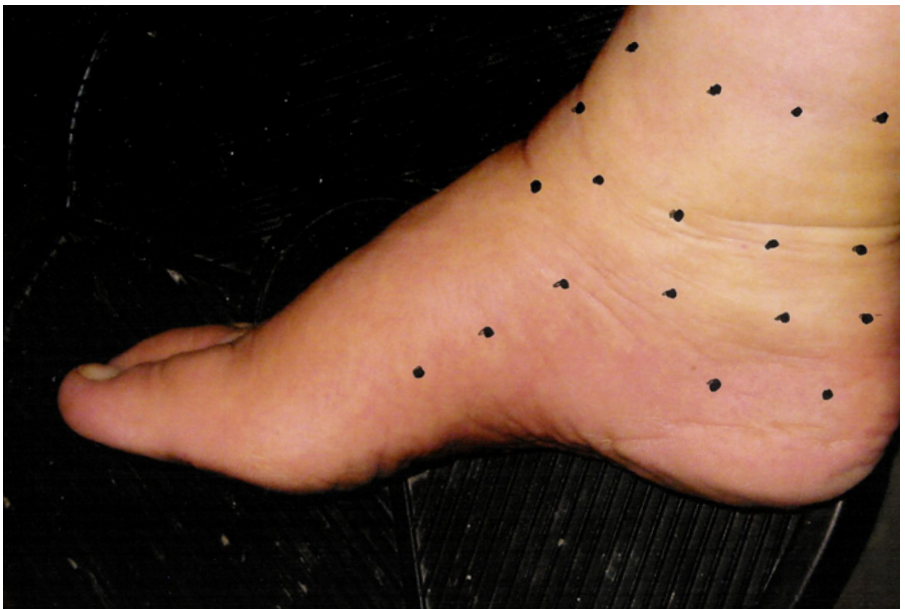
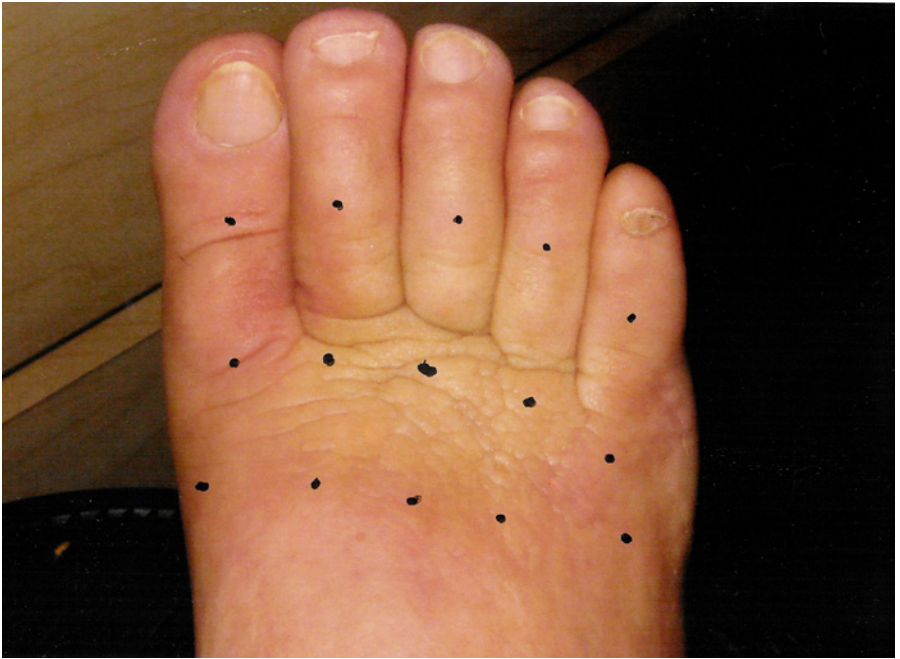Fibrosis from upper thigh to foot, with foot most fibrotic and dry cracking skin on top of foot.

This patient is self treating every second day. Treatment time is extensive (about 1 hour).

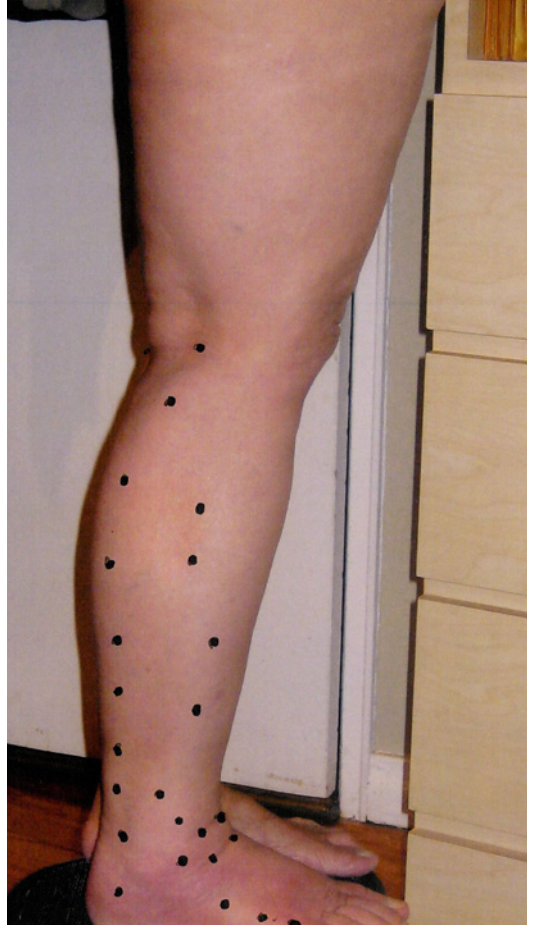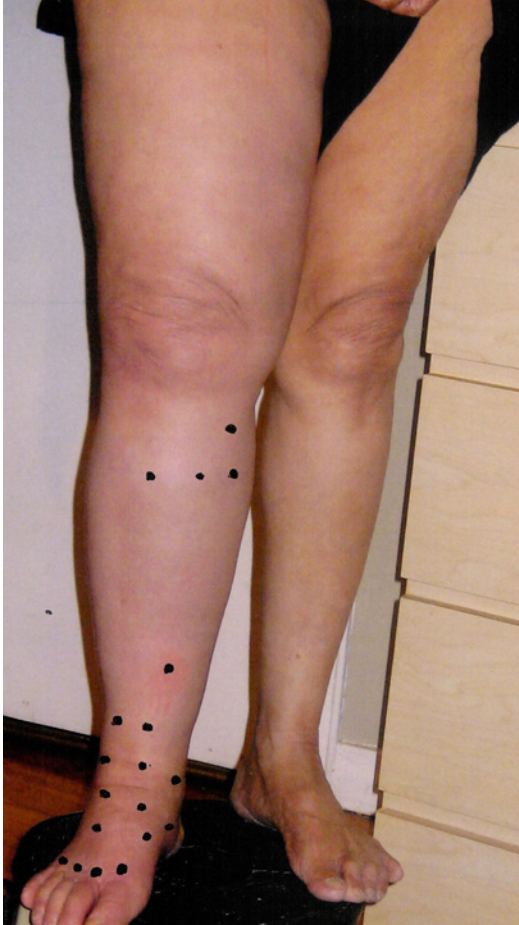After two months the patient reported some softening. She went to see her doctor (primary, who's checking the progress with the laser treatment) after 2 months of treatment. He definitely saw some improvement. The swelling of the leg and thigh has gone down , but the foot remains fibrotic. The overall skin feel is softer.

The only other treatment being done with this patient are exercises instructed by her lymph therapist.





case study 3



case study 4

case history 4

Female - 60 years

Female 60 years old. After eye surgery the patient had to stay face down for 22 out of 24 hours for 10 days (to repair retina).

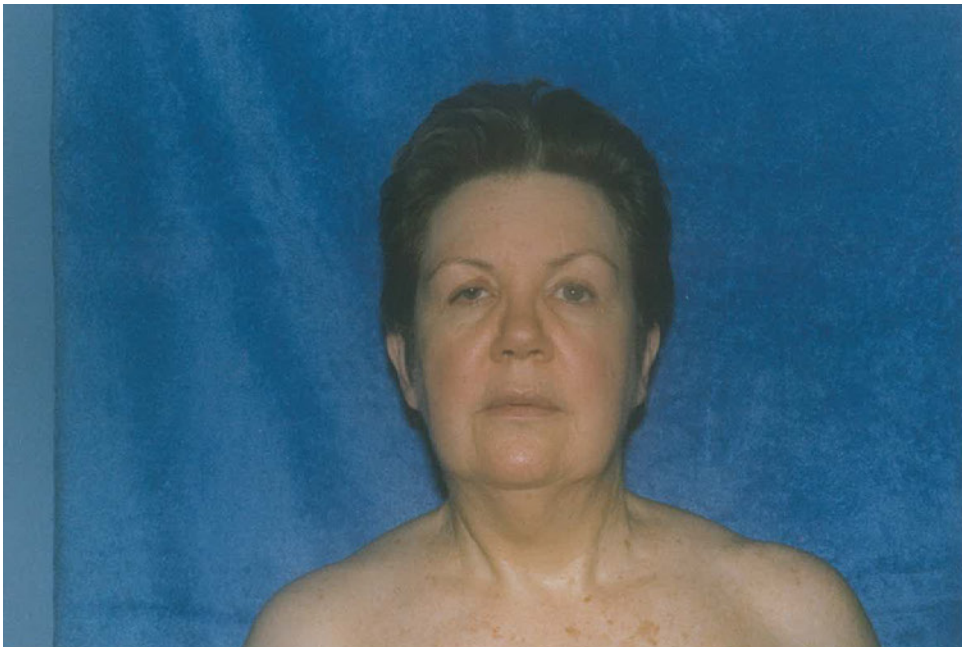Post surgery swelling evident in photo.

Treatment was laser therapy (1 min per point), down neck and near cheek.

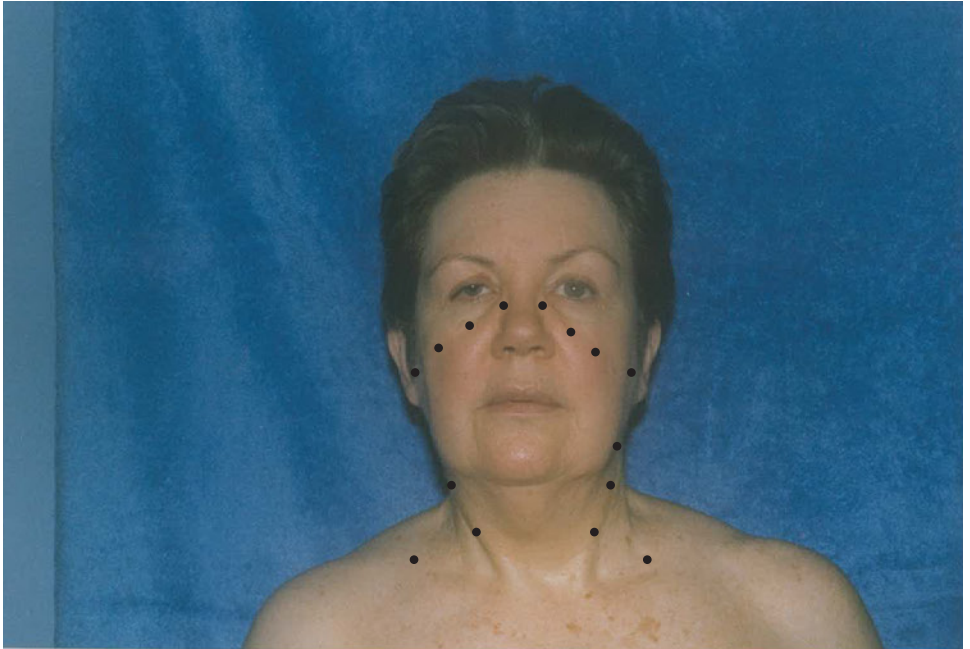
MLD followed laser treatment (approx 30 mins).

After photo taken immediately after treatment.

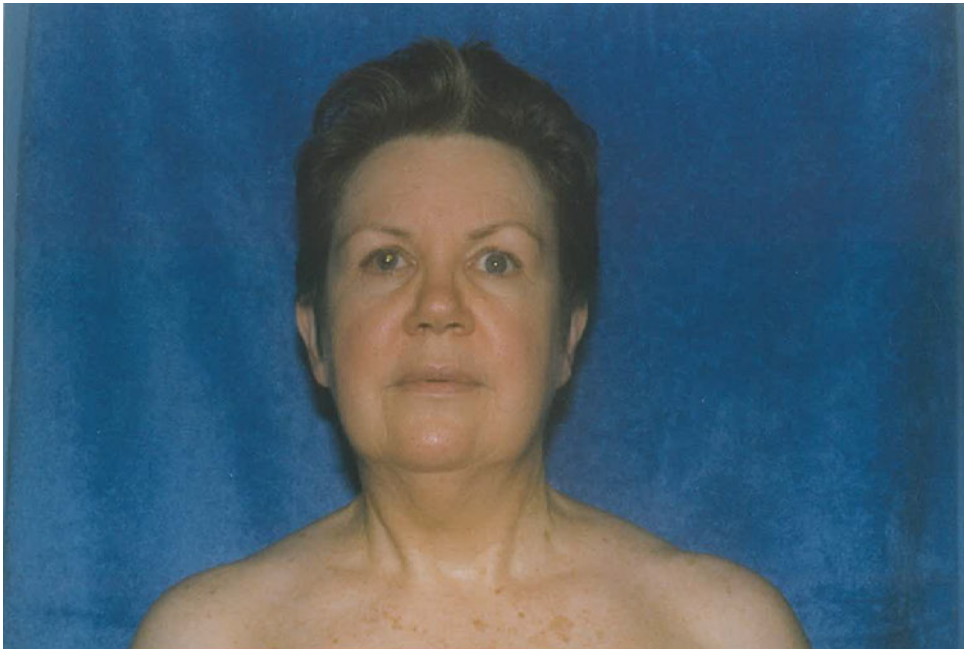Before Treatment



Treatment Areas



After Treatment



case study 5

case history 5

Female - 73 years

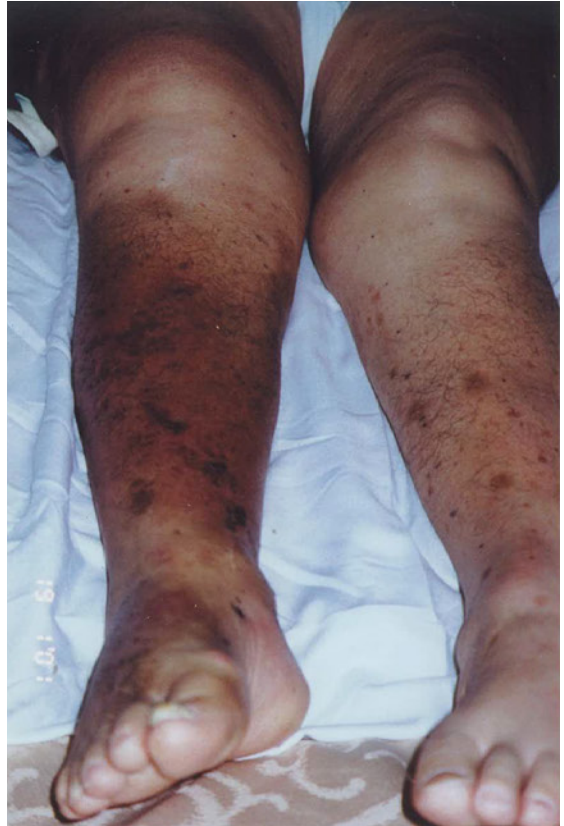Female 73 years old. Primary lymphoedema (from puberty). Patient was in a nursing home and presented with very hard discoloured legs, over-growth of wart-like tissue on both legs, fungal infection in toes.

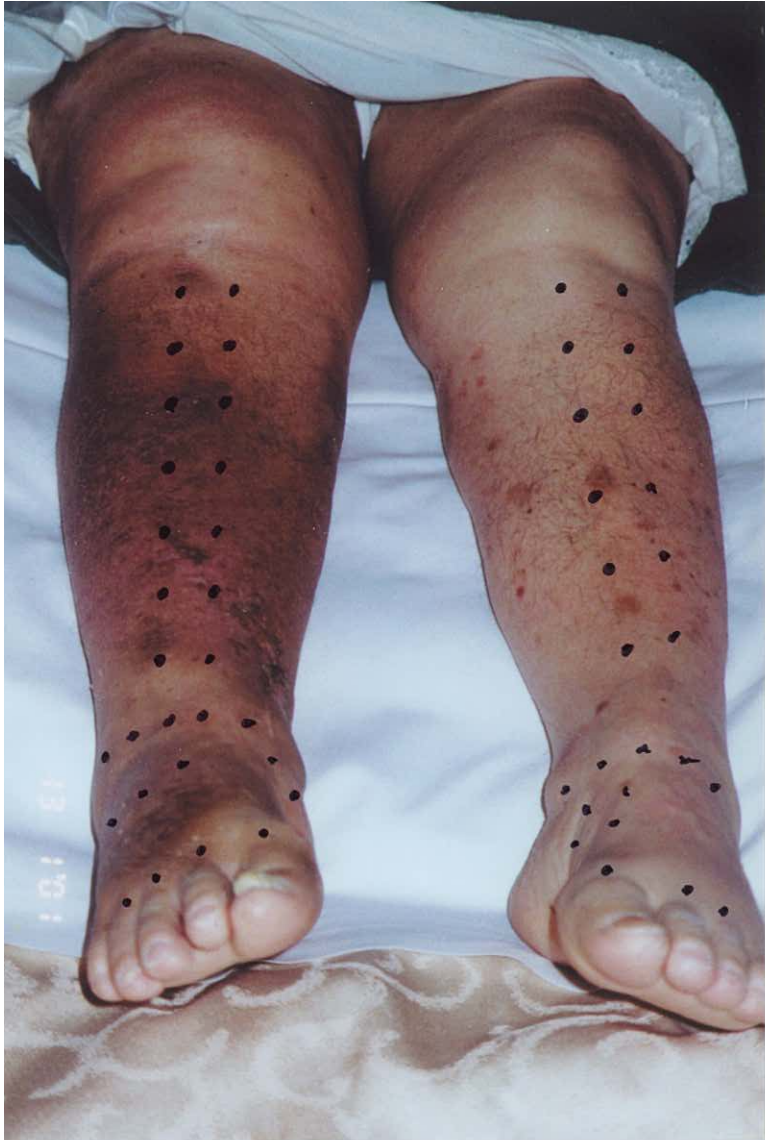Both legs were paralysed through spine injury.

Laser (1 min per point) to feet, calf and either side of leg bones. MLD and bandaging followed daily for 14 days. Discolouration disappeared, wart-like growth disappeared.

After 14 days of intensive treatment, treatment was reduced to 1 treatment every two weeks (laser and MLD). Leg swelling reduced, hardness reduced.

Treatment continued for 5 months (patient passed away).





RianCorp Pty Ltd

7 Fleet St Richmond
South Australia 5033

p + 61 8 8232 8822

f + 61 3 9558 6335

sales@riancorp.com

www.riancorp.com